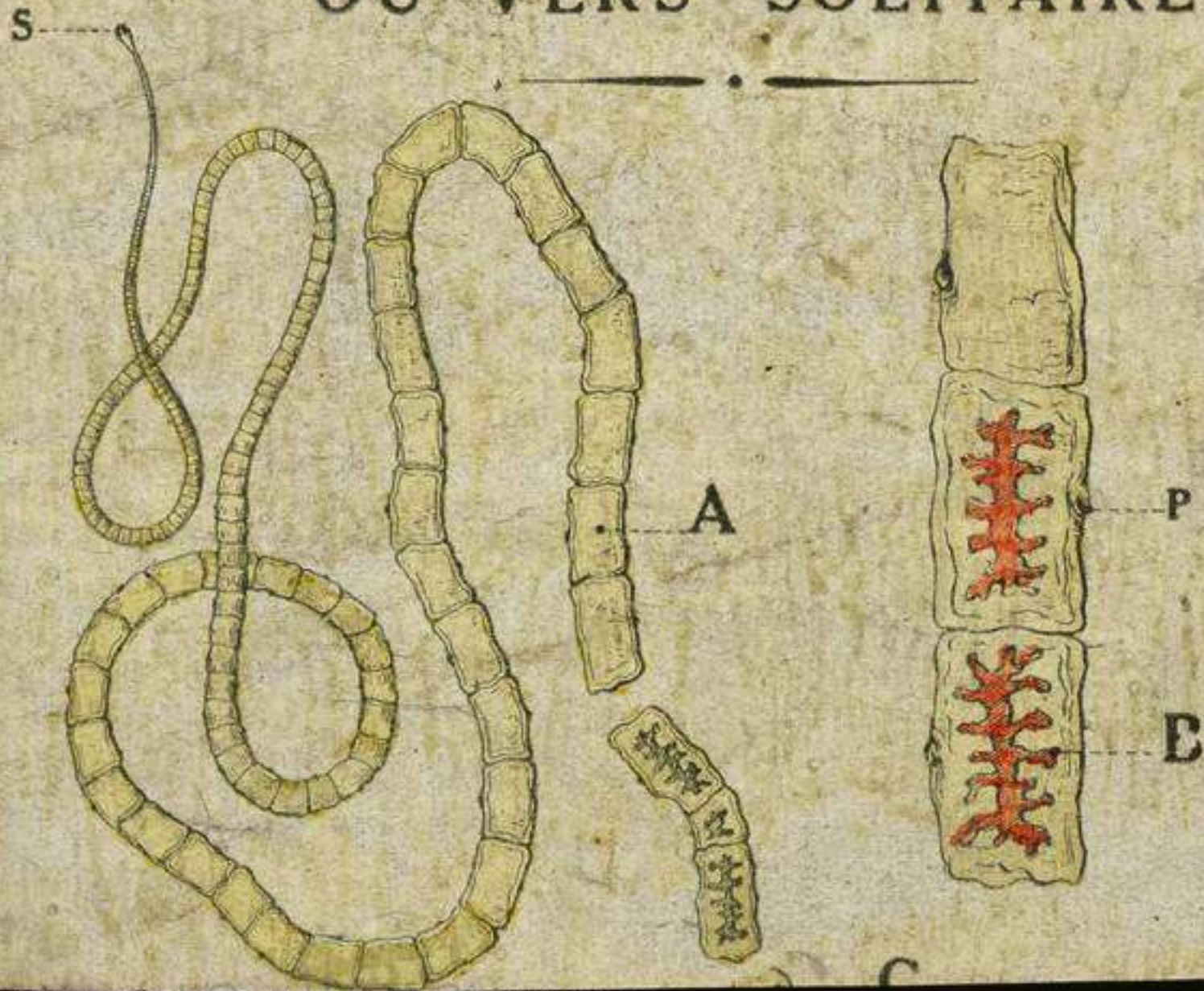



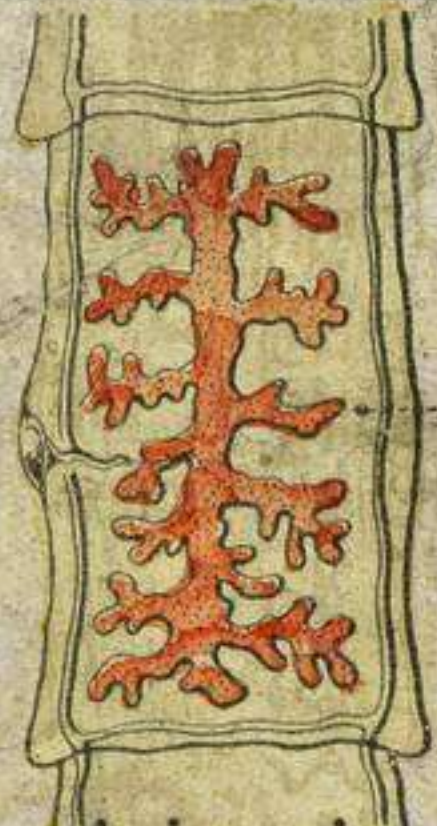
LES TENIAS OU VERS SOLITAIRES



II.

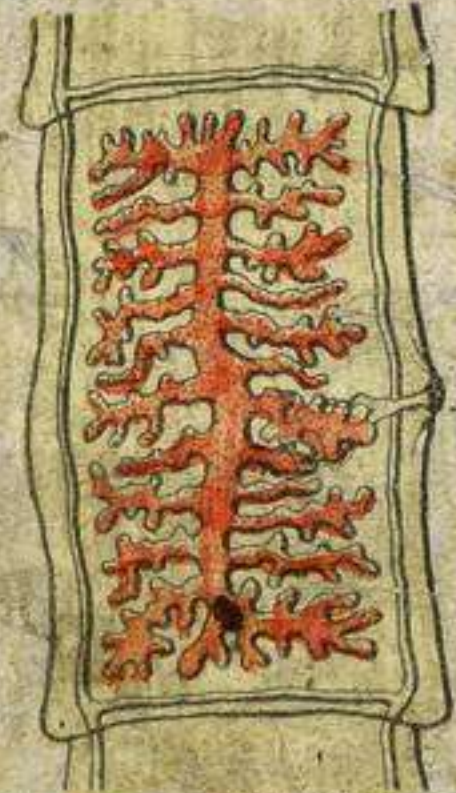SCOLEX DES TENIAS





A

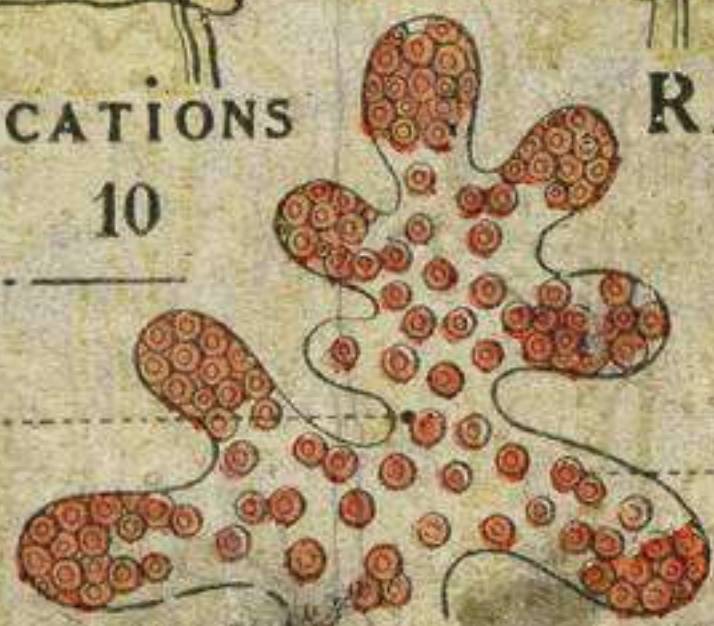RAMIFICATIONS
5 à 10



B

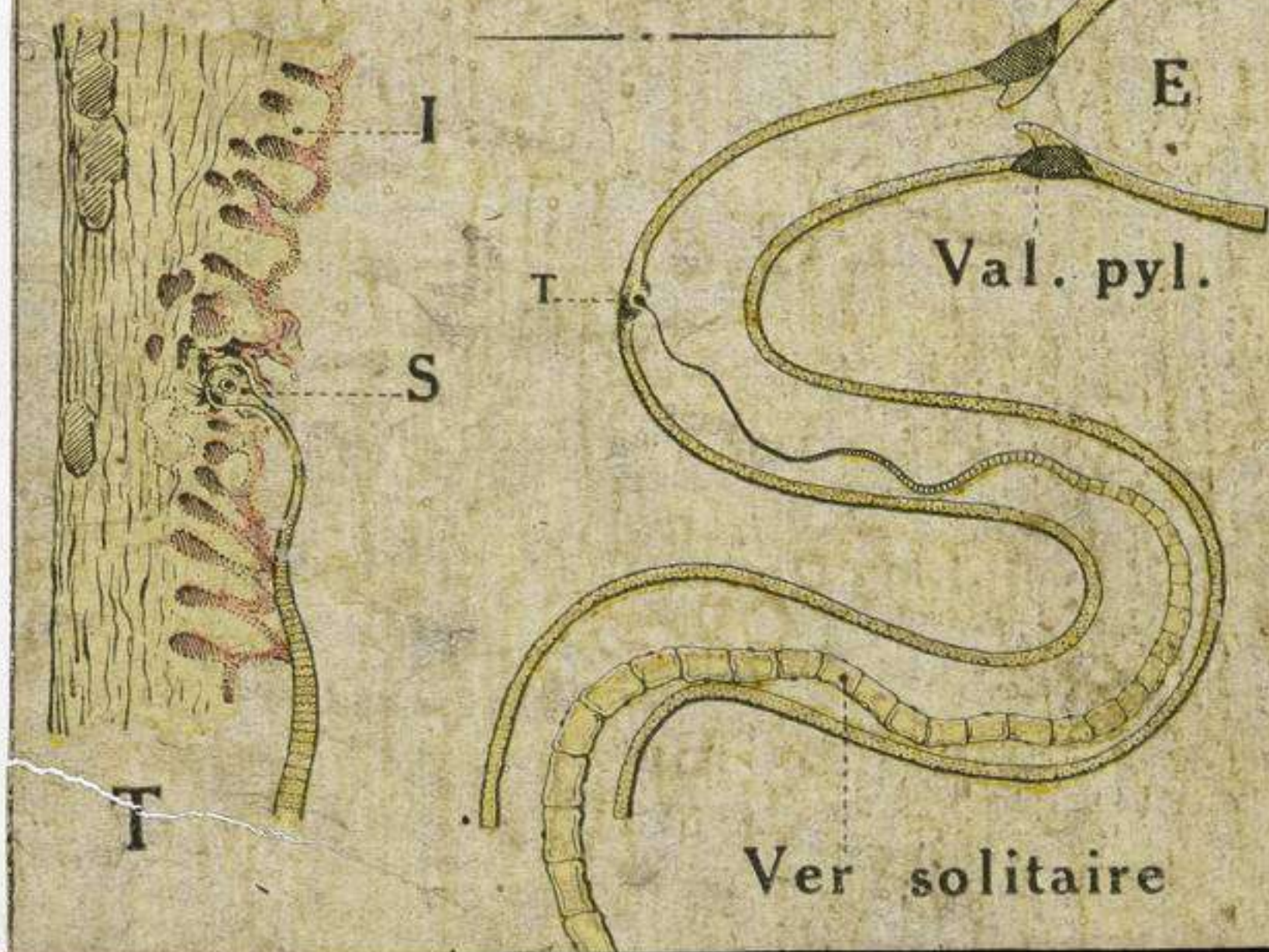
RAMIFICATIONS
15 à 30

G




ŒUFS .

IV. LE VER SOLITAIRE
DANS L'INTESTIN



DES TENIAS



TÉNIA ARMÉ

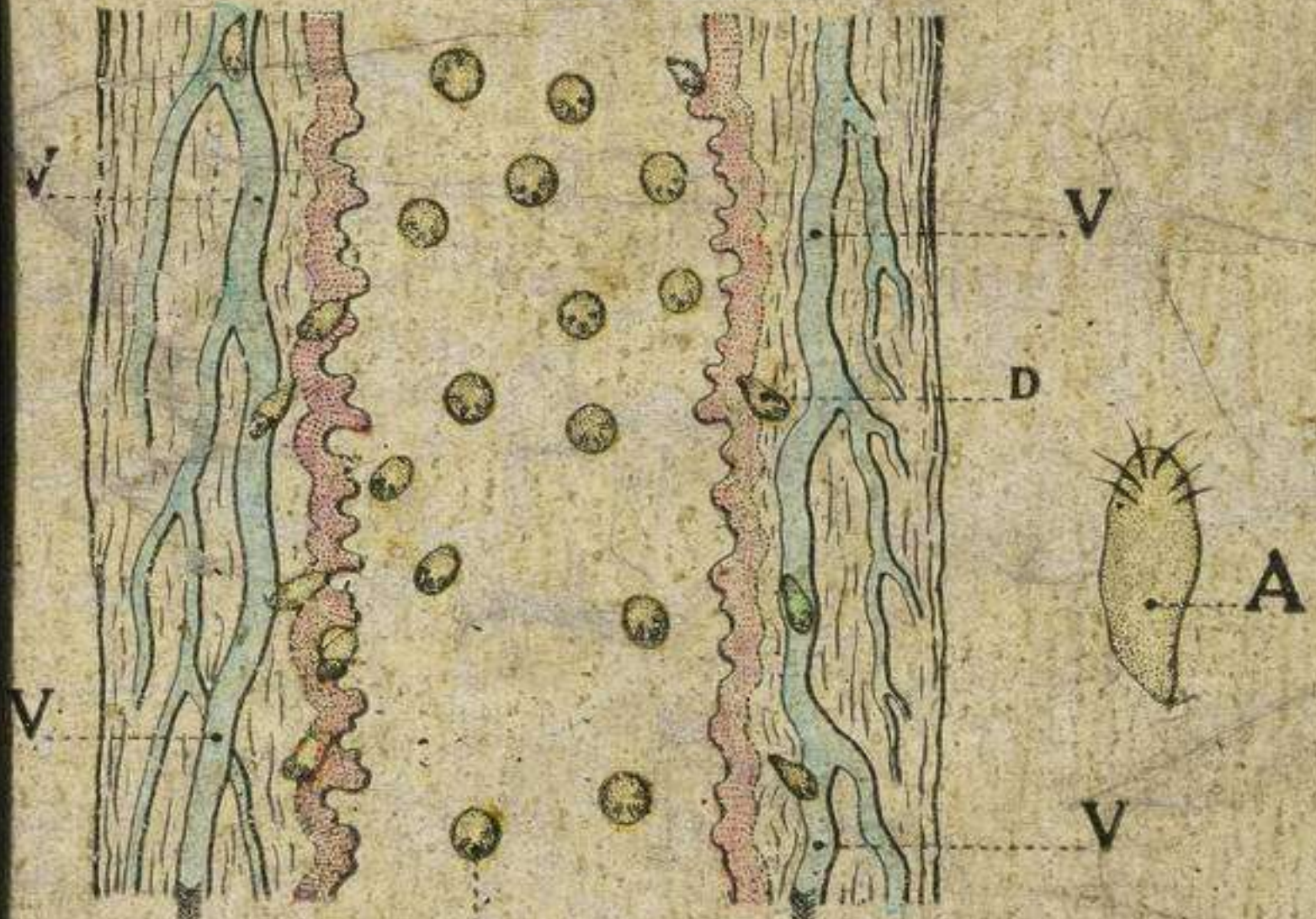


T. SANS CROCHETS



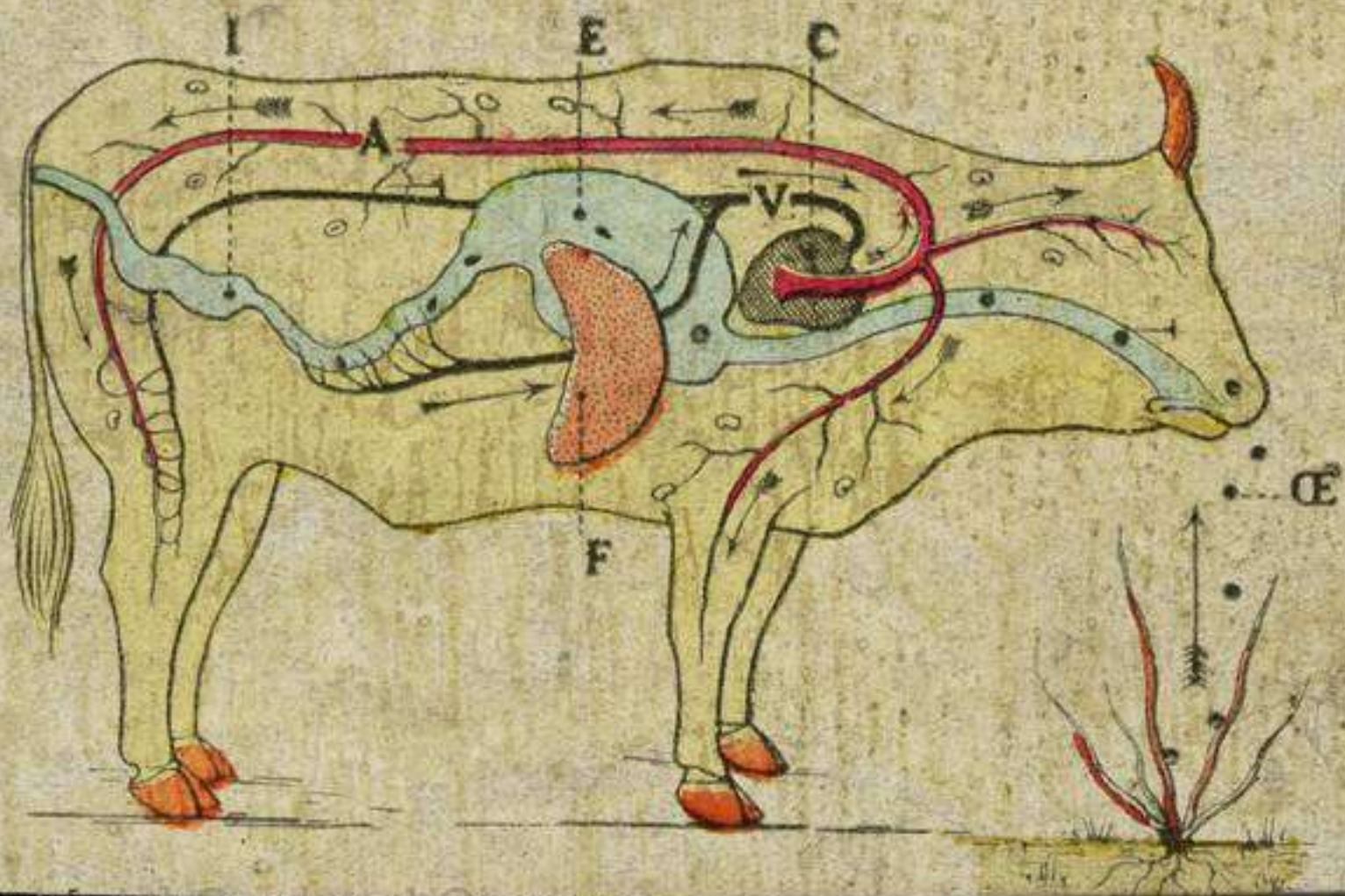
EMBRYON HEXACANTHE

VI. EMBRYONS DANS L'INTESTIN.




EMBRYONS

VII. LE CYSTICERQUE
CHEZ LE BŒUF



LIBRES ET ENKYSTES

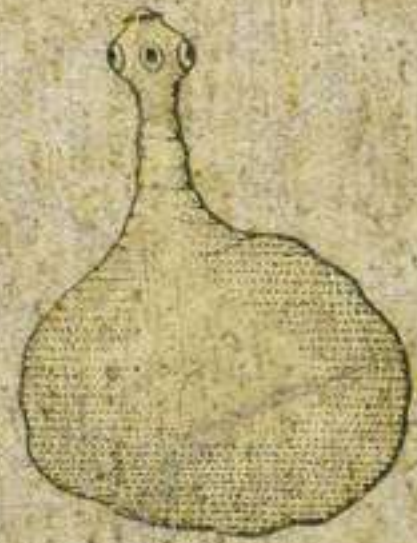

C. invaginé .



D

VIII.

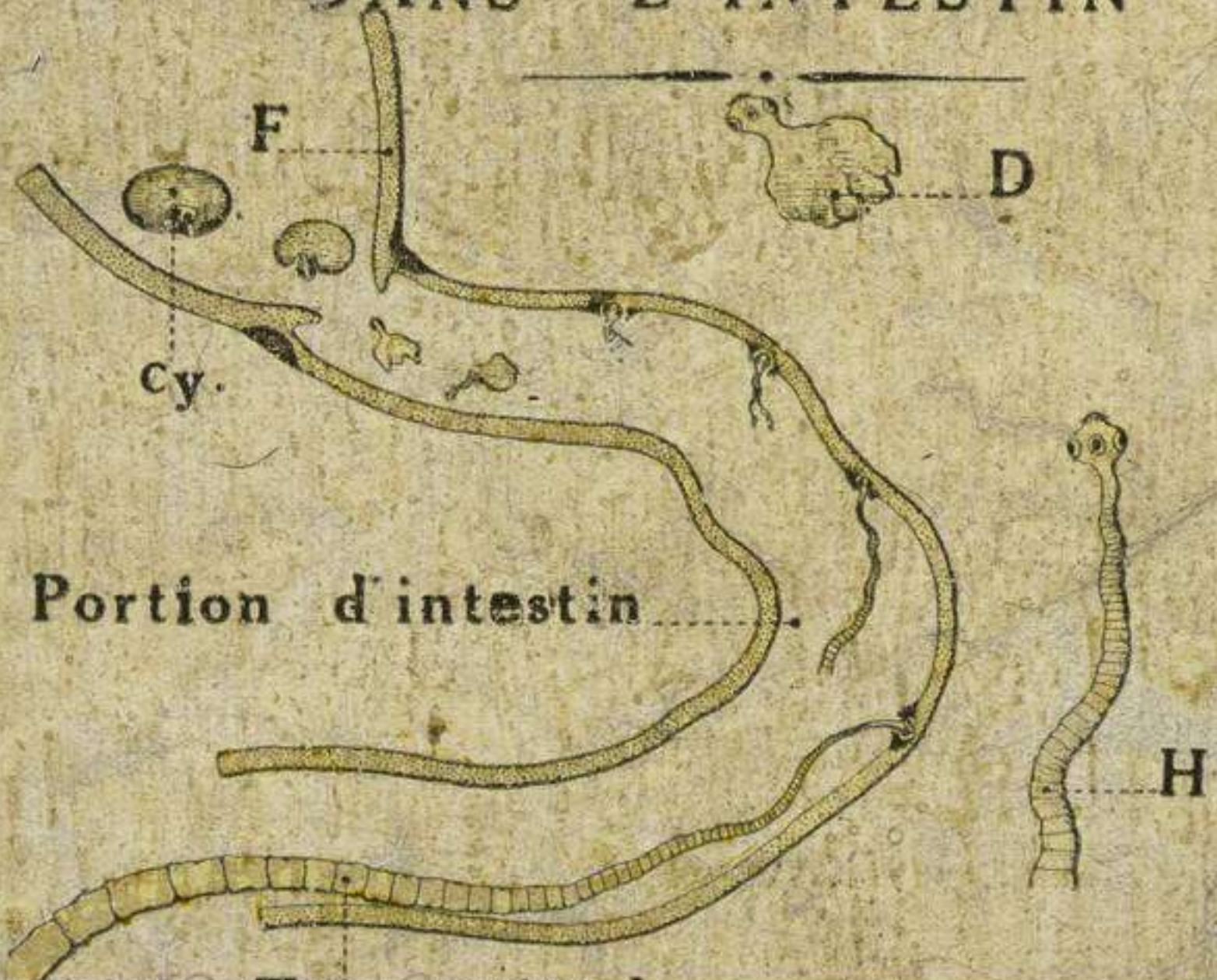


C. dévaginé .

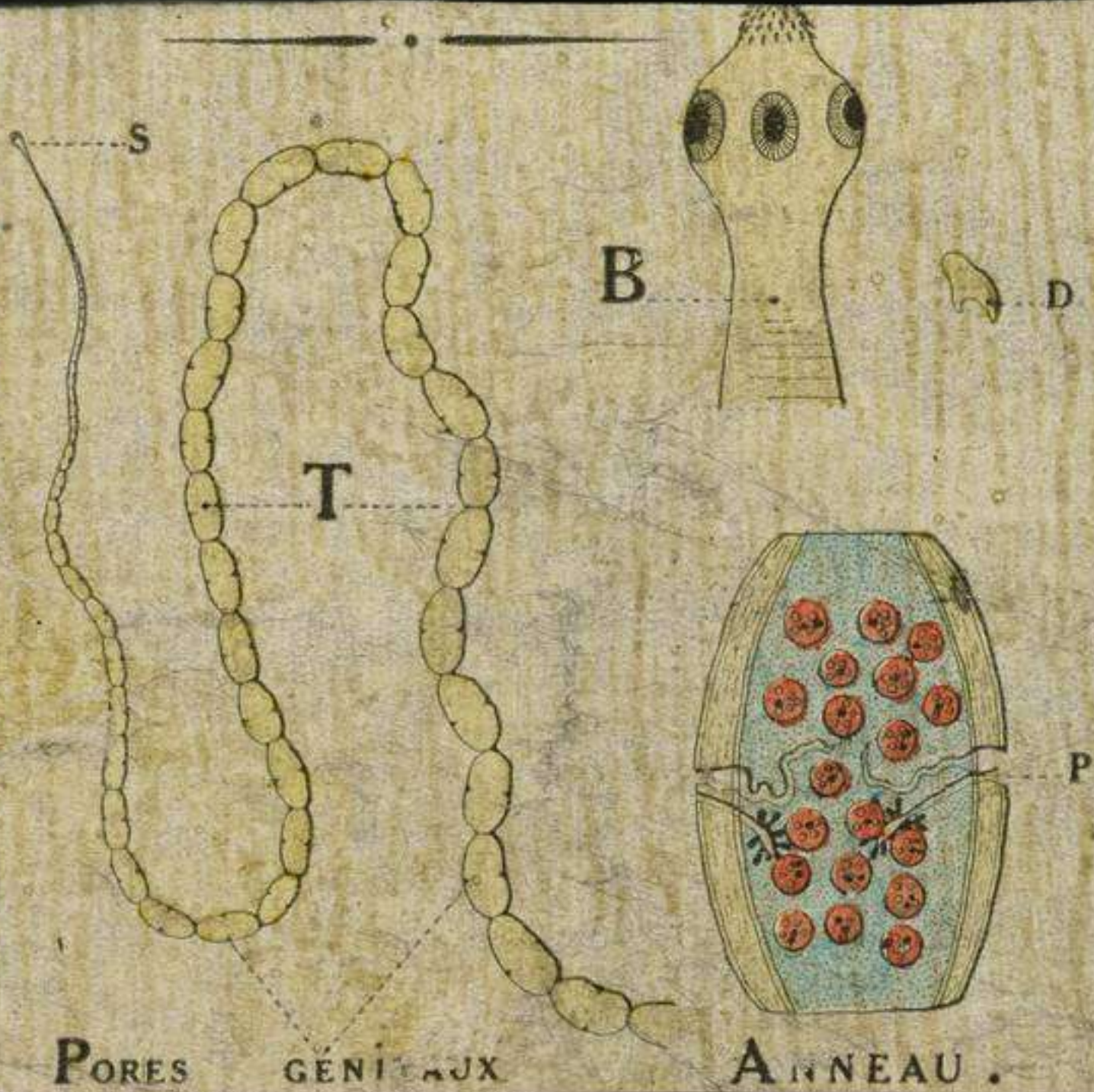
CYSTICERQUES

MAZO. PARIS

IX. CYSTICERQUES
DANS L'INTESTIN



TÉNIA DU CHIEN

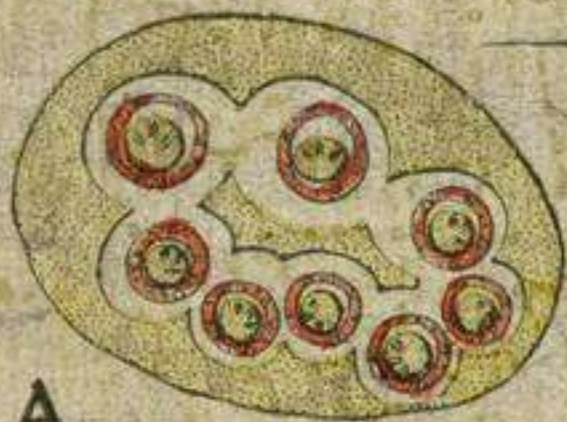


PORES GÉNÉRAUX

ANNEAU.

ŒUFS ET CYSTICERQUES

(TÉNIA du CHIEN)




A

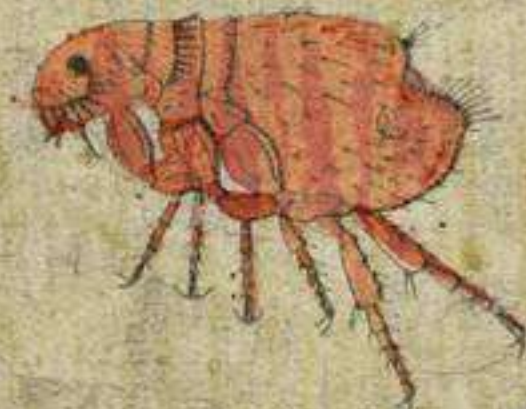

C

CYSTICERCOÏDE .

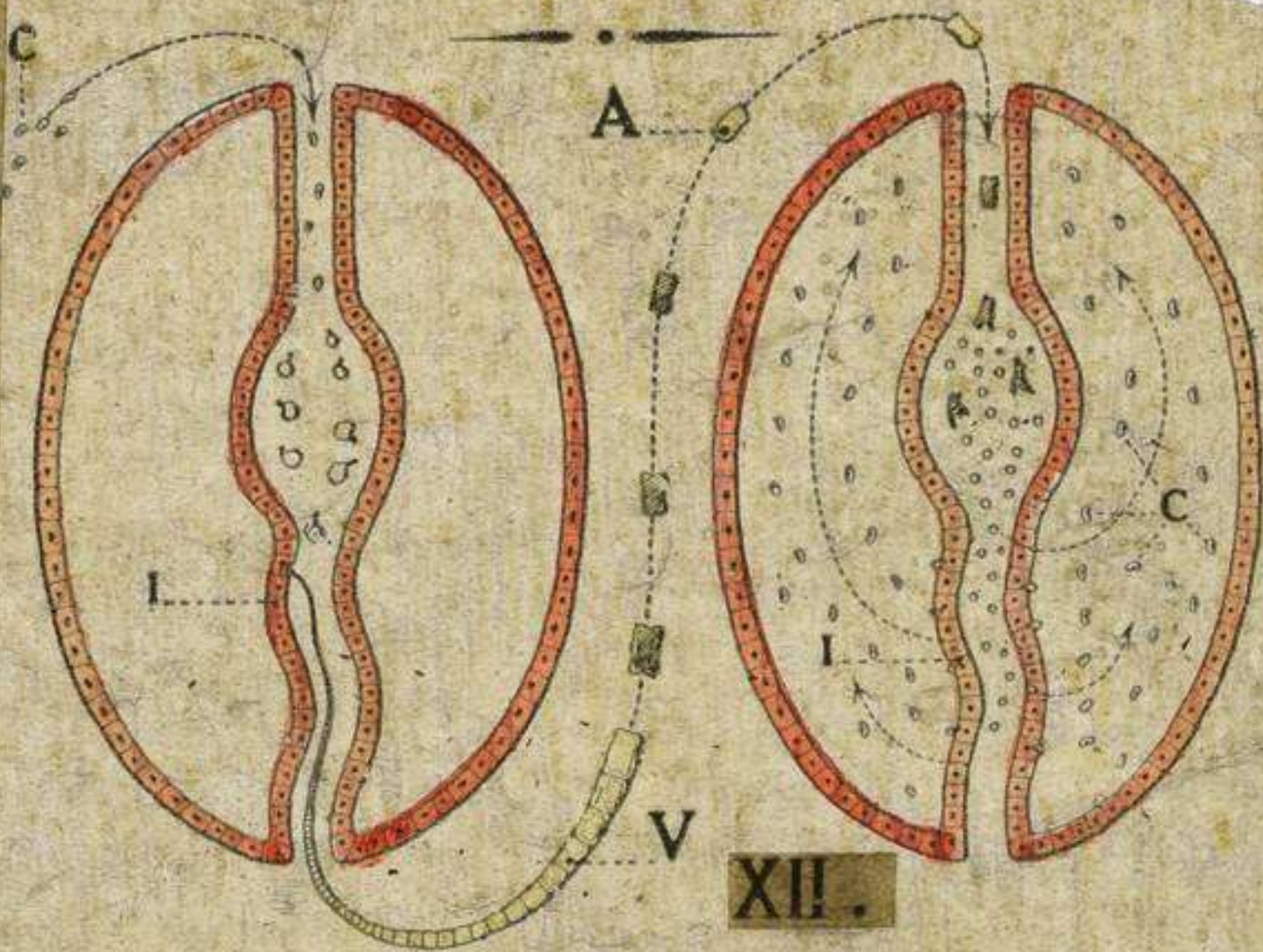


B



PUCE DU CHIEN .

TÆNIADES



L'HOMME

LE PORC OU LE BŒUF